


Available online on 15.10.2021 at <http://jddtonline.info>

# Journal of Drug Delivery and Therapeutics

Open Access to Pharmaceutical and Medical Research

Copyright © 2021 The Author(s): This is an open-access article distributed under the terms of the CC BY-NC 4.0 which permits unrestricted use, distribution, and reproduction in any medium for non-commercial use provided the original author and source are credited



Open Access Full Text Article



Case Study

## ATT-Therapy Induced DRESS: A Case Report

Navya Sri G, Feba Stanly, Georgina Sarah, Prasad Bali, Varsha Dalal\*

KLE College of Pharmacy, Hubballi and KIMS Hubli, Karnataka 580031, India

### Article Info:



#### Article History:

Received 19 August 2021  
Reviewed 13 September 2021  
Accepted 19 September 2021  
Published 15 October 2021

#### Cite this article as:

Sri G N, Stanly F, Sarah G, Bali P, Dalal V, ATT-Therapy Induced DRESS: A Case Report, Journal of Drug Delivery and Therapeutics. 2021; 11(5-S):1-5

DOI: <http://dx.doi.org/10.22270/jddt.v11i5-S.5060>

#### \*Address for Correspondence:

Varsha Dalal, KLE College of Pharmacy, Hubballi and KIMS Hubli, Karnataka 580031, India

### Abstract

A severe adverse reaction called Drug Reaction with Eosinophilia and Systemic Symptoms (DRESS syndrome), is usually described by eosinophilia, fever, swollen lymph nodes, severe skin rash and extensive systemic association. It is distinguished by a lengthy latency period, which is characteristic drug reaction with eosinophilia and systemic symptoms (DRESS). Formerly known as drug-induced delayed multi-organ hypersensitivity syndrome (DIDMOHS) or drug-induced hypersensitivity (DIHS). There are a variety of clinical symptoms associated with the syndrome yet it is still poorly understood. Drugs most commonly implicate in Anticonvulsants are the most common cause of DRESS syndrome, followed by sulfonamides and a variety of anti-inflammatory medications. Anti-tubercular therapy (ATT) is rarely associated with DRESS syndrome. We present the case of a 60-year-old female patient who had previously been treated with Anti-tubercular Therapy for Tubercular Meningitis (ATT). She was admitted to the hospital with presenting complaints of vomiting, burning micturition, fever associated with chills, generalized swelling and reddish skin all over the body including facial puffiness. The problem was successfully resolved by refraining from the offending medication and administering supportive care. Thus, the case illustrates the necessity of considering anti-tubercular drug reactions even when symptoms are delayed.

**Keywords:** Anti-tubercular Therapy (ATT), Drug Reaction with Eosinophilia and Systemic Symptoms (DRESS), Adverse drug reaction (ADR), Drug-induced, Systemic symptoms syndrome,

## INTRODUCTION

The Drug Reaction with Eosinophilia and systemic symptoms (DRESS) syndrome can be defined as a drug-induced hypersensitivity syndrome which is a rare occurrence of reaction that involves primarily a large-scale skin rash, lymphadenopathy, fever and hematological changes like eosinophilia, thrombocytopenia and increased lymphocyte count. There is an inflammatory reaction affecting the inner organs involved in this type of reaction. This reaction occurs within two months of the initiation of drug therapy and includes the above-mentioned signs and symptoms.<sup>1</sup> DRESS may or may not cause a dermatosis; the degree to which skin is involved is also variable. Therefore, the "R" in DRESS was changed from "rash" to "reaction."<sup>2</sup> Defects in detoxification leading to the generation of reactive metabolites and immunological reactions, delayed acetylation, and the reactivation of human herpes, such as the Epstein-Barr virus, have all been associated to its development.<sup>3</sup>

DRESS is the most rarely seen severe adverse drug reaction, and it affects approximately 1 in a thousand to 1 in a ten thousand patients who take the drug. It is found that the mortality rate is nearly 10%.<sup>4</sup> As a result of literature search, the majority of cases were classified as definite or probable cases of DRESS. Since epidemiological data on disease incidence and underlying causes are lacking, it is difficult to predict the true incidence of DRESS.

The most commonly reported offending drugs are antiepileptics and antibiotics, including sulfonamides, gold salts, and antitubercular drugs, where anti-TB drugs are the rarest.<sup>5</sup> In the event of DRESS syndrome, immediate removal of suspect drugs is necessary.

The DRESS caused by Anti-Tubercular drugs raises specific concerns:

- It is difficult to identify the drug causing DRESS when the four anti-TB drugs (Rifampicin, Isoniazid, Pyrazinamide, Ethambutol) are administered concurrently.
- As the condition will worsen, the treating physician may consider resuming the medication. However, restarting the medication may sometimes result in a worse situation

We present a case of ATT-induced DRESS syndrome in this paper.

## CASE REPORT

A 60-year-old female patient arrived to the emergency department of KIMS Hubli complaining of nausea for one month, burning micturition for 2 to 3 days, fever and chills for 1 to 2 days, generalized swelling, and reddish skin all over her body for 8 to 10 days. Her health history includes Type 2 Diabetes Mellitus and Hypertension for 3 years, Tubercular meningitis on anti-tubercular therapy for one month, and seizures for one month. Erythematous

maculopapular rashes with itchy reddish lesions were present all over the body including facial puffiness for 8 days. Patient was being treated with anti-tubercular medication since 29<sup>th</sup> December 2020.

Laboratory investigations were performed on the patients, as shown in Table no.1

**Table 1**

Laboratory Tests	Day 1	Day 2	Reference Range
Haemoglobin (gm/dl)	10.8		12-16
TLC (million cells/cmm)	10.52		4.5-11
RBC (million cells/cmm)	4.09		4.2-5.4
DC % L, M, N, E, B	12.6,8.7,55.1,22.9,0.7		
AEC (cells/cmm)	2000		
Platelets (lacs/cmm)	306		1.5-4.5
T. Bilirubin (mg/dl)		4.2	0.2-1.0
SGOT/AST (IU/L)		181	<40
SGPT/ALT (IU/L)		213	<40
ALP (IU/L)		103	44-147
RBS	120	150	
Urea (mg/dl)	20	15	10-15
Serum Creatinine (mg/dl)	0.3	0.4	0.6-1.3
Serum sodium (mmol/L)	117		135-145
Serum Potassium (mEq/L)	2.6		3.5-5.5

Dermatological examination revealed generalized erythema, multiple ill-defined erythematous with patches over the face, upper limb, lower limb, trunk. Dusky necrotic macules over

palms and soles, facial puffiness, erythema in genitalia and oral candidiasis. Dermatological impression concluded with DRESS secondary to Anti-Tubercular Therapy.



Figures 1, 2 and 3: Patchy skin eruptive scales all over the body.

They advised discontinuing the offending drug. The patient was recommended with Intravenous Fluids, Inj. Dexamethasone 2 cc twice a day for 3 days, Inj. Pantoprazole once a day, Liquid Paraffin local application twice a day, Tablet Chlorpheniramine HS, Tablet Cetirizine once a day for a period of 3 weeks.

The patient was treated with Piperacillin/ Tazobactam 4.5 g after test dose, four times per day, Metronidazole 500 mg three times a day, Pantoprazole 40 mg once a day,

Dexamethasone 8 mg (2cc) twice a day and Ondansetron 4 mg twice a day for a period of five days.

Along with the above-mentioned medications the patient was on her regular medications i.e., Telmisartan 40 mg in the night, Aspirin 75 mg daily, Atorvastatin 20 mg in the night, Levetiracetam 500 mg twice a day, Potassium chloride 2 ampoules in 500 ml Normal saline on the fourth day and was on Insulin therapy.

Following a week of treatment in the hospital, the patient was discharged and the treatment continued for three more weeks.

After the treatment, the patient's signs and symptoms resolved rapidly and his skin reaction improved. The patient provided informed consent.

## DISCUSSION

Bocquet et al named DRESS Syndrome in 1996. Based on certain criteria, he diagnosed it as –

- Widespread cutaneous eruptions on the skin.
- Rise in temperature.
- Eosinophilia > 1500/mm<sup>3</sup> or the presence of abnormal lymphocytes are hematological symptoms.
- Lymphadenopathy with or without involvement of internal organs, such as pericarditis, hepatitis, or pneumonitis.<sup>6</sup>

Most frequently, drugs associated with DRESS syndrome are anticonvulsants, antibiotic agents, anti-inflammatory medicines and a few others.<sup>5</sup>

Drug history, history and examinations of skin signs, blood tests, peripheral tubes, absolute eosinophil counts, liver function, renal, electrolytes, chest x-ray, plain abdomen, and 2D echocardiogram make up the assessment of DRESS.<sup>7</sup> Histological studies demonstrate unspecific inflammatory patterns such as eczema, interphase dermatitis,

exanthematous pustules or generalized multiforme-like erythema.<sup>8</sup> A skin biopsy is not usually recommended for DRESS.

**Table 2:**<sup>5</sup>

Anti-Convulsants	Phenytoin Carbamazepine Phenobarbitone Lamotrigine
Anti-Inflammatory	NSAIDS
Antibiotics	Sulphonamides Cotrimoxazole Penicillins Minocycline Nitrofurantoin
Anti-Retroviral therapy (ART)	Abacavir Nevirapine
Others	Dapsone Allopurinol Gold salts

**Table 3: RegiSCAR scoring for DRESS**<sup>(7)</sup>

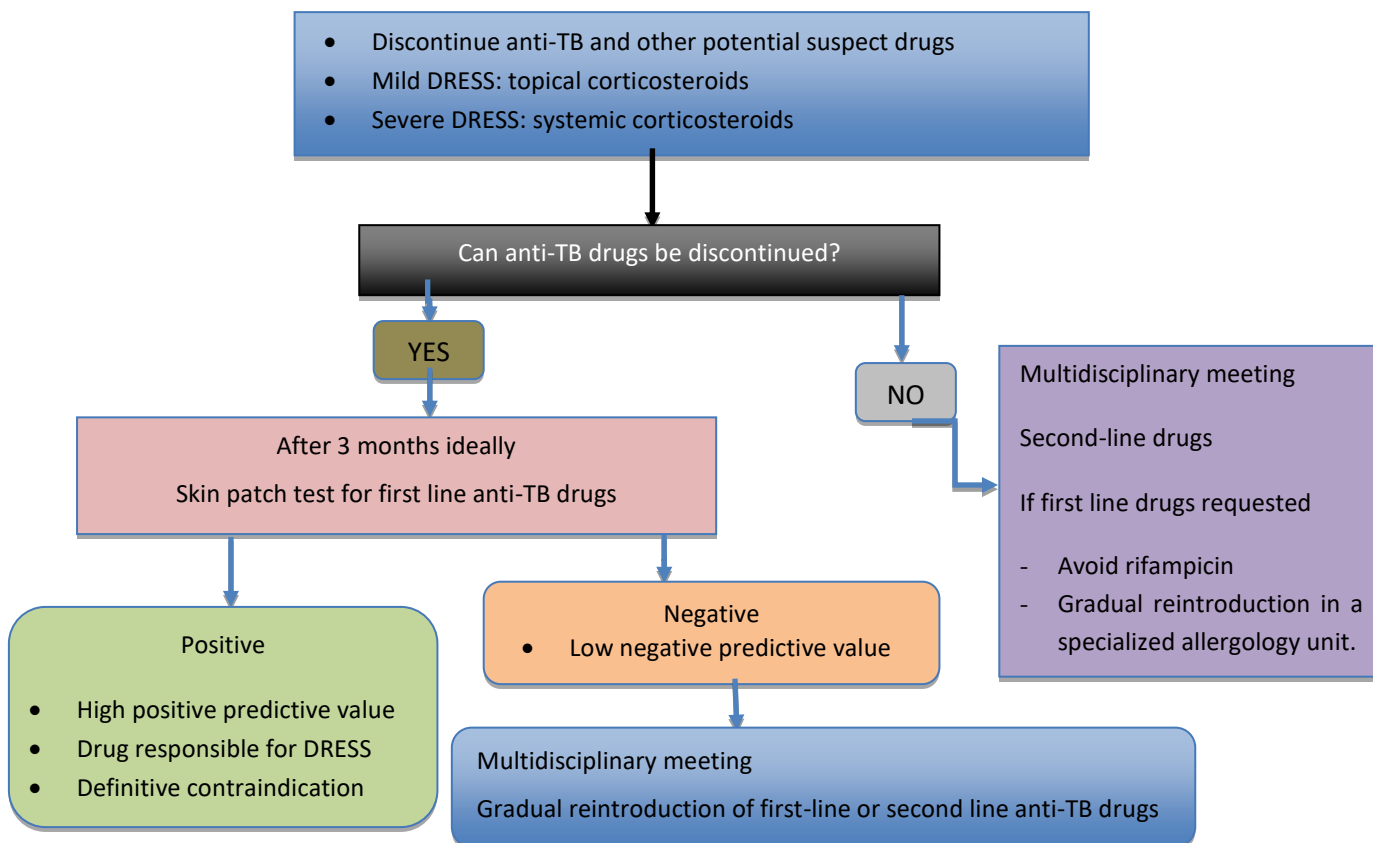
PARAMETER	No	Yes	Unknown
Fever (>38.5°C)			
Enlarged lymph nodes (>=2 sites, >1cm)			
Atypical lymphocytes			
Eosinophils 700-1499 or 10-19.9% >=1500 or >=20%			
Skin Rash Extent >50% At least 2 of; edema, infiltration, purpura, scaling Biopsy suggesting DRESS			
Internal organ involvement One Two or more			
Resolution in >15 days			
At least 3 biological investigations done and negative to exclude alternative diagnosis			

Final score: <2=no case; 2-3=possible case; 4-5=probable case; >5= definitive case<sup>7</sup>

According to the studies conducted by P.N Conan et. al., a skin biopsy is usually required after discontinuing all the drugs that is suspected to involve DRESS.<sup>(8)</sup> If DRESS is confirmed, 2-6 months after the recovery, skin patch test is usually recommended. The results of the skin patch test for

diagnosis can vary from one medicine to the next, and its negative predictive value is less than 100.<sup>9,10</sup>

The strategy to diagnose when DRESS syndrome is suspected to happen due to any anti-TB drug as follows:

**Algorithm 1:**<sup>8</sup>

Discontinue anti-TB treatment for at least one month after DRESS recovery, then perform skin patch tests to guide drug re-introduction. When stopping anti-TB medicines is not an option, second-line TB therapy should be started temporarily. If immediate reintroduction of first-line TB drugs is needed, Rifampicin should be avoided, and a dermatology specialist should be consulted.<sup>4</sup> Systemic corticosteroids must be given when there is cardiac, respiratory, or severe hepatic involvement. Topical steroids are used to treat mild DRESS.<sup>8</sup>

The pathogenesis of DRESS may include slow acetylation and detoxification defects that cause formation of reactive metabolite following with immunologic reactions.<sup>9</sup>

The treatment usually involves, initial discontinuation of the offending drug. The gold standard of therapy includes treatment using corticosteroids. The French society of Dermatology recommendations suggests that systemic corticosteroids at 1mg/kg/day of prednisone in patients involving transaminitis, renal involvement, cardiac involvement and pneumonia. Subsequent treatment using IV Ig at 2gm/day for 5 days in patients involving renal and respiratory failure. Additional treatment includes usage of steroids with ganciclovir combination in patient with reactivation of HHV-6.<sup>10</sup>

## CONCLUSION

Though it is a rare condition, the introduction of antitubercular drugs should only proceed after skin patch testing with Isoniazid (INH), Rifampicin (RMP), Ethambutol (EMB) and Pyrazinamide (PZA). It is important to recognize such phenomenon because it is potentially a life-threatening condition, and therefore it is important to report such cases to Pharmacovigilance Centers. Instant withdrawal of the offending drug is mandatory.

## CONFLICT OF INTEREST

The author declares no potential conflicts of interest with respect to research, authorship, and/or publication of this article.

## ACKNOWLEDGEMENT

The author thanks KLE College of Pharmacy, Hubballi and KIMS Hubli for all the support.

## REFERENCES

1. Drug reaction with eosinophilia and systemic symptoms - Wikipedia [Internet]. En.wikipedia.org. 2021 [cited 24 August 2021]. Available from: [https://en.wikipedia.org/wiki/Drug\\_reaction\\_with\\_eosinophilia\\_and\\_systemic\\_symptoms](https://en.wikipedia.org/wiki/Drug_reaction_with_eosinophilia_and_systemic_symptoms)
2. Criado P, Criado R, Avancini J, Santi C. Drug reaction with Eosinophilia and Systemic Symptoms (DRESS) / Drug-induced Hypersensitivity Syndrome (DIHS): a review of current concepts. *Anais Brasileiros de Dermatologia*. 2012; 87(3):435-449. <https://doi.org/10.1590/S0365-05962012000300013>
3. Oliveira A, Carvalho R, Martins A, Reis J. Acute Hepatitis in the DRESS Syndrome [Internet]. 2021 [cited 24 August 2021]. Available from: <https://doi.org/10.1016/j.jpgc.2016.06.001>
4. Cacoub P, Musette P, Descamps V, Meyer O, Speirs C, Finzi L et al. The DRESS Syndrome: A Literature Review. *The American Journal of Medicine*. 2011; 124(7):588-597. <https://doi.org/10.1016/j.amjmed.2011.01.017>
5. Saxena, Puneet & Chadha, Deepak & Goyal, Rishika. (2021). Case Report Of Dress Syndrome. *The journal of the Royal College of Physicians of Edinburgh*. 50. <https://doi.org/10.4997/JRCPE.2020.414>
6. Prusty B, Momin M, Goud Y, Ramineni K, Perveen S. DRESS Syndrome- Uncommon Drug Reaction with Common Disease Treatment: A Case Report. *Journal of Microbiology and*

- Infectious Diseases. 2020; 225-229.  
<https://doi.org/10.5799/jmid.839481>
7. De A, Rajagopalan M, Sarda A, Das S, Biswas P. Drug reaction with eosinophilia and systemic symptoms: An update and review of recent literature. *Indian Journal of Dermatology*. 2018; 63(1):30. [https://doi.org/10.4103/ijid.IJD\\_582\\_17](https://doi.org/10.4103/ijid.IJD_582_17)
8. Gest N, Ingen-Housz-Oro S, Gener G, Bellanger M, Henn A, Gallien S et al. Drug reaction with eosinophilia and systemic symptoms (DRESS) syndrome due to ethambutol. *Médecine et Maladies Infectieuses*. 2018; 48(4):302-305.  
<https://doi.org/10.1016/j.medmal.2018.03.001>
9. Tohyama M, Hashimoto K. New aspects of drug-induced hypersensitivity syndrome. *The Journal of Dermatology*. 2011; 38(3):222-228. <https://doi.org/10.1111/j.1346-8138.2010.01176.x>
10. Dar W, Sofi N, Latief M, Dar I, Kasana B. Levetiracetam induced drug reaction with eosinophilia and systemic symptom syndrome. *Indian Journal of Dermatology*. 2016; 61(2):235.  
<https://doi.org/10.4103/0019-5154.177777>